



## Diagnostic Case Study And Treatment Of Giardiasis In Cat At Rvet Clinic Bogor

Niken Hardiyanti<sup>a</sup>, Risa Tiuria<sup>b\*</sup>, Rizal Arifin Akbari<sup>c</sup>

<sup>a</sup>Veterinary Medicine Study Program, School of Veterinary Medicine and Biomedical Sciences, IPB University, Bogor, 16680

<sup>b</sup>Division of Parasitology and Medical Entomology, Department of Animal Disease and Veterinary Public Health, School of Veterinary Medicine and Biomedical Sciences, IPB University, Bogor, 16680

<sup>c</sup>Veterinarian of RVet Animal Clinic, Bogor, 16320

\*corresponding author: [risati@apps.ipb.ac.id](mailto:risati@apps.ipb.ac.id)

---

### Abstract

*Giardia* sp. is a digestive tract protozoan that can cause Giardiasis. This disease is classified as a water-borne parasitic disease. Giardiasis infects cats, especially cats who have a habit of drinking raw water or sewage. This case study aims to learn the treatment given to cats with Giardiasis. The cat in this study was named Memed, a cat with a mixed Persian breed and was 1.5 years old. Memed came to the RVet Bogor clinic with a grievance of diarrhea without blood for six days and was not accompanied by vomiting. The owner explained the cat was often released and drank water carelessly. Memed was diagnosed with Giardiasis after discovering of *Giardia* cysts in stool samples that were observed using the fecal flotation technique. Memed was given medical therapy using Metronidazole and vitamin B12 preparations. After the 5th post-therapy day, Memed was declared cured of giardiasis, characterized by the consistency returning to normal and no *Giardia* cysts found in the feces.

*Keywords: Giardiasis, Cats, Fecal Flotation, Metronidazole*

Copyright © 2023 JRVI. All rights reserved.

---

### Introduction

Having a pet is a trend in today's society. One of the pets with high interest and the community's favorite is the cat. Cats are attracted because they have various body shapes, eyes and fur colors. Pet cats have a very close relationship with their owners, because of the nature of cats that are easy to care for and easy to adapt (Bengi et al., 2017). However, cats are one of the hosts in the development and spread of infectious diseases caused by parasites (Zakaria & Ardiansyah 2020). Therefore, the closeness between cats and humans can have a negative impact if the animal is infected with zoonotic parasites (Akbari et al., 2018).

Parasites are classified into two types, namely endoparasites and ectoparasites. Two types of endoparasites infect cats, namely worms and protozoa. One of the most common digestive tract protozoa that infect cats is *Giardia* sp. (Pagati et al., 2018). According to Akbari et al., (2018), *Giardia* sp. which can attack cats and humans is *Giardia duodenalis* or *Giardia lamblia*. These protozoa can cause a disease called Giardiasis. According to Vassalos et al., (2017), Giardiasis is classified as a significant parasitic disease that can spread through water (waterborne disease) along with *Cryptosporidium* sp. and *Entamoeba histolytica*. Therefore, cats with a habit of drinking raw water or sewage are very susceptible to infection with this disease.

The typical clinical symptom experienced by cats when they expose to Giardiasis is non-specific diarrhea that lasts a long time. However, it may become asymptomatic, so supporting tests are needed to confirm the diagnosis of Giardiasis (Stepinska et al., 2021). The usual supporting test is a microscopic examination by looking at the presence or absence of trophozoites or cysts from the stool samples examined. Microscopic analysis can do by the method of fecal flotation. The proper diagnostic test will determine the accuracy of the therapy given to realize the healing of infected animals. Metronidazole is a therapeutic preparation widely used to treat Giardiasis in cats (Scorza & Lappin 2003).

## **Materials and Methods**

### ***Clinical Examination in Patients Suspected of Giardiasis***

The patients conducted the clinical examination on patients suspected of Giardiasis by inspection, palpation, and auscultation. This examination includes weighing, measuring body temperature, calculating heart rate, pulse, respiratory rate, checking skin and mucous membrane turgor.

### ***Cat Stool Sample Collection***

Stool samples from the cat, a patient at the Rvet Bogor clinic suspected of Giardiasis. Samples were obtained by taking fresh feces directly from the defecation area of approximately 3-5 grams and then put into a petri dish.

### ***Stool Examination Simple Flotation Method***

Stool examination using a simple flotation method was carried out by weighing 2 grams of cat feces, then they put the feces into a beaker and added 58 ml of flotation solution. The mixture was stirred until homogeneous. After that, the solution one was poured into a new beaker while filtering so that the feces didn't not carry away. Filtering does 3-4 times. The filtered solution was allowed to stand for 2 minutes, then poured into a test tube until it was packed and formed a convex meniscus. The test tube was closed using a cover glass and waited for 5 minutes. The cover glass is moved and attached to the object glass. The sample is ready to be examined under a light microscope with 40x of magnification.

### ***Evaluation of Treatment Results in Giardiasis Patients***

Evaluation of treatment results by testing the infected animal's feces using a simple flotation method. The number of cysts in this method counts in 5 fields of view and then averaged. A simple evaluation of treatment for Giardiasis patients by observing the form of cat feces on day 0 and 5 post-therapy, counting the number of *Giardia* cysts on days 0 and 5 post-

therapy in 5 visual fields and then averaging, comparing the evaluation results. On days 0 and 5 post-therapy, the parameters of the form of stool scores and the average number of cysts from 5 visual fields.

## Results and Discussion

### *Results of Signaling, Anamnesis, and Physical Examination*

A mixed Persian cat named Memed came to the RVet Bogor clinic. This cat is 1.5 years old, a gray mix of white and male. Memed came with grievances of diarrhea for six days with the consistency of watery stools, without blood, and not accompanied by vomiting. During diarrhea, Memed didn't lose appetite and drink. The owner explained the cat was often released and drank water carelessly, including raw water and sewage. In addition, the owner also provided information that his cat had received a complete vaccine. The clinical examination showed Memed's weight was 3.4 kg, body temperature was 38 °C, heart rate was 92 times/minute, and respiratory rate 32 times/minute. Memed looks limp and pale. The clinical examination data of Memed shows that Memed has lost weight.



Fig. 1 Cat patient named Memed

The anamnesis and clinical examination found that Memed was often let loose by the owner, so Memed was diagnosed with a gastrointestinal protozoan infection. Robbie et al., (2020) supported that the maintenance management of the owner also influences the occurrence of protozoan infection. For most pets released outside the house by the owner, the higher the probability of a case of protozoa infection. Most of these protozoan infections can cause diarrhea, despite sometimes being asymptomatic. In this case, supportive examination in the form of stool examination establishes the diagnosis. A stool examination can help to determine the type of gastrointestinal parasite that infects the cat patient.

### *Diagnostic Techniques with Stool Examination*

Confirmation of the diagnosis in cases of a cat patient suspected of being infected by gastrointestinal protozoa by a simple flotation test using a saturated NaCl flotation agent. This method aims to determine the type of protozoa quickly and precisely. The flotation method is suitable for examining feces containing a few protozoa cysts. In addition, this method also has several advantages, such as taking a short time, economical cost, and not require complex equipment. The results of the simple flotation method of stool examination can see in Figure 2.

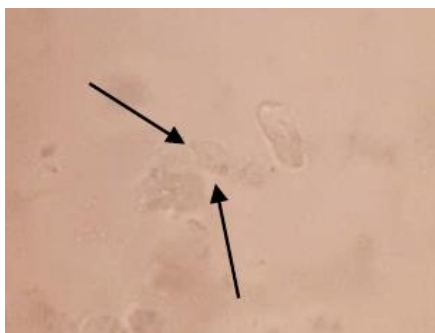


Fig. 2 The results of examination with fecal flotation method in cat patient

Based on the stool examination using the flotation method (Figure 2), *Giardia* sp. cysts were found in cat patient feces samples. The *Giardia* cysts are oval, have a nucleus, and are fibrous. According to Levine (1995), *Giardia* sp in the cyst stage has two to four nuclei and several residual fibers from trophozoite organelles. The number of *Giardia* cysts found in 5 fields of view and averaged results in  $>1$  cyst/field of view. The findings of the *Giardia* cyst determined that the cat patient infects by *Giardia* sp. The diagnosis on the anamnesis carries out that the cat patient liked to be released outside the house and drank raw water or sewerage. Cats who have the habit of drinking raw water or sewerage are very susceptible to Giardiasis because this disease is a parasitic disease that can spread through water (waterborne disease) (Tayyab et al., 2017).

Infections caused by *Giardia* sp. are known as Giardiasis. Cat patient infected with *Giardia* sp. showed clinical signs of non-specific watery diarrhea. It is caused by the activity of *Giardia* in the intestine, which produces several toxins including enterotoxins, proteinases, and lectins. Lectins on the surface of *Giardia* serve as aids in parasite attachment to host cells during infection. The contact between trophozoites and intestinal cells can also lead to the release of metabolic enzymes and proteases that aid in parasite colonization (Vivancos et al., 2018). The attached trophozoite *Giardia* sp. usually does not invade the epithelium, surrounding tissue, or enter the blood vessels; therefore, *Giardia* sp. is confined to the intestinal lumen. The adhesions that occur can cause damage to the intestinal microvilli, villous atrophy, intestinal crypt hyperplasia, increased intestinal permeability, and damage to the brush border, which causes a decrease in the secretion of disaccharide enzymes (Harun et al., 2019). Decay in the brush border of the intestine will cause an increase in fluid secretion so that acute or chronic diarrhea will occur (Al-Kahfaji & Alsaadi 2019).

### **Medical Therapy**

The treatment given to the cat patient was Metronidazole and appropriate vitamin B12. Metronidazole is an anti-parasitic drug with a broad spectrum and is active against protozoa and anaerobic bacteria (Tedjasulaksana, 2016). This preparation has an effectiveness of 60-100% as a drug for Giardiasis therapy. According to Argüello-García et al., (2020), this drug is the first choice for treating of several anaerobic pathogens, including the gastrointestinal protozoan *Giardia* sp. This drug will attack antigens by interfering with DNA and nucleic acid synthesis (Robbie et al., 2020). The administration of Metronidazole preparations in cat patient according to the dosage recommendations by Akbari et al., (2018), which is 20-25 mg/kg BW for 7-14 days orally.

According to Vivancos et al., (2018), *Giardia* infection can cause malabsorption of vitamin B12 leading to deficiency. The deficiency of this vitamin is one of the causes of chronic diarrhea in cats. Therefore, giving vitamin B12 is very helpful in treating diarrhea in cats infected by *Giardiasis*. Vitamin B12 was given to the cat patient at a dose of 0.025 mg/kg BW for 7-14 days orally, as recommended by Wientarsih et al., (2017).

Evaluation of the therapy result in the cat patient was carried out by observing the stool score and the number of *Giardia* cysts on day 0 and day 5 post-therapy. The results of the evaluation of treatment can be seen in Figure 3. Treatment on day 0 was indicated by the consistency of watery stools and the number of *Giardia* cysts >1 per field of view. After the 5th post-therapy day, the stool showed a solid consistency, and a *Giardia* cyst wasn't found in the stool. The difference in treatment results was very clearly seen on day 0 and day five post-therapy. Accordingly, the cat patient was cured of *Giardiasis* infection after 5th day of therapy.

Prevention of *Giardiasis* in cats by giving **A** cats drinking water using **B** ed water and monitoring so that cats do not drink sewer water or toilet water, which have the potential as a habitat for *Giardia* cysts (Akbari et al., 2018). *Giardia* sp. Therefore, prevention measures can also carry out by purifying water using chlorine. The administration of chlorine in water purification is considered adequate for killing enteropathogenic organisms, but to kill *Giardia* cysts requires a higher chlorine concentration (Harun *et al.*, 2019). According to Wardhana (2017), steps to prevent *Giardiasis* in cats can also do by giving trophozoite extract vaccination.




Fig. 3 The results of treatment evaluation (A) The form of feces on the 0 days of therapy, (B) *Giardia* cyst on the 0 days of therapy, (C) The form of the feces on the 5th day after therapy, (D) No *Giardia* cyst was found on the 5th day of therapy

## Conclusion

Confirmation of the diagnosis using a simple flotation technique in a cat patient who experiences prolonged diarrhea, weight loss, and has a habit of drinking raw water can be

used to diagnose cases of Giardiasis. Cat patient with Giardiasis was treated with Metronidazole at a dose of 20-25 mg/Kg BW for 7-14 days and vitamin B12 at a dose of 0.025 mg/Kg BW for 7-14 days orally. The cat patient was declared cured of Giardiasis on the 5th post-therapy day characterized by stool consistency that returned to normal and no *Giardia* cyst found in the feces.

## Acknowledgment

The authors thank the RVet Animal Clinic for permission and field assistance during this research. The author declares no conflict of interest with interested parties in this study.

## Reference

- Akbari, R.A., Wientarsih, I., Prasetyo, B.F., Madyastuti, R. 2018. Terapi giardiasis penyebab diare non-spesifik pada kucing. *ARSHI Vet Lett.* 2(1): 7–8.
- Al-kahfaji, M.S.A., Alsaadi, Z.H. 2019. *Giardia Lamblia* and Giardiasis. *J Univ Babylon Pure Appl Sci.* 27(5): 66–74.
- Argüello-García, R., Leitsch, D., Skinner-Adams, T., Ortega-Pierres, M.G. 2020. Drug resistance in *Giardia*: Mechanisms and alternative treatments for giardiasis. *Adv Parasitol.* 107: 201–282.
- Bengi, W.T.M., Erina., Darniati. 2017. Isolasi dan identifikasi *Pseudomonas aeruginosa* pada kasus ear mites kucing domestik (*Felis domesticus*) di Kecamatan Syiah Kuala, Banda Aceh. *Jimvet.* 1(2): 161–168.
- Harun, H., Sennang, N., Rusli, B. 2019. Giardiasis. *J Kesehat Tadulako.* 5(3): 4–12.
- Levine, N.D. (Ed.). 1995. *Buku Pelajaran Parasitologi Veteriner.* Gadjah Mada University Press, Yogyakarta.
- Pagati, A.L., Suwanti, L.T., Anwar, C., Yuniarti, W.M., Sarmanu., Suprihati, E. 2018. Prevalence of gastrointestinal protozoa of cats in animal hospital and animal clinic in Surabaya. *J Parasite Sci.* 2(2): 61–66.
- Robbie, M.H., Fajeria, A.L., Pratiwi, L., Aeka, A. 2020. Protozoa gastrointestinal: helmintiasis dan koksidiosis pada kucing domestik. *MKH.* 31(3): 97–110.
- Scorza, A.V., Lappin, M.R. 2003. Metronidazole for the treatment of feline giardiasis. *Journal of Feline Medicine and Surgery.* 6. 157-160.
- Stepinska, A.P., Piekarska, J., Gorczykowski., Bania, J. 2021. Genotypes of *Giardia duodenalis* in household dogs and cats from Poland. *Acta Parasitol.* 66: 428–435.
- Tayyab, M., Haseeb, A., Rehman, H.U., Saeed, K., Ali, S., Naveed, M., Ullah, I., Javed, A., Inayatullah., Khan, S. 2017. Detection of *Giardia lamblia* by microscopy in different water sources of district D.I Khan, KP, Pakistan. *JEZS.* 5(3): 1-5.
- Tedjasulaksana, R. 2016. Metronidasol sebagai salah satu obat pilihan untuk periodontitis marginalis. *J Kesehat Gigi.* 4(1): 19-23.
- Vassalos, C.M., Charlett, A., Vassalou, E., Mpimpa, A., Dounias, G., Tzanakaki, G., Mavridou, A., Spanakos, G. 2017. Assessment of a commercially available multiplex real-time PCR kit against direct immunofluorescence and nested PCRs for the detection of *Giardia lamblia*, *Cryptosporidium* sp., and *Entamoeba histolytica* in sewage. *Desalin Water Treat.* 91: 101–111.
- Vivancos, V., González-Alvarez, I., Bermejo, M., Gonzalez-Alvarez, M. 2018. Giardiasis: characteristics, pathogenesis and new insights about treatment. *Curr Top Med Chem.* 18(15): 1287–1303.
- Wardhana, AH. 2017. *Giardia intestinalis* assemblage e sebagai zoonosis baru pada ternak. *WARTAZOA.* 27(4): 197–205.

- Wientarsih, I., Prasetyo, B.F., Madyastuti, R., Sutardi, L.N., Akbari, R.A. 2017. *Obat-Obatan Untuk Hewan Kecil*. IPB Press, Bogor.
- Zakaria, R., Ardiansyah, S. 2020. Potential analysis of toxoplasmosis distribution in wild cats (*Felis silvestris*) in some markets of Sidoarjo district through microscopic identification of *Toxoplasma gondii*. *Medicra*. 3(2): 59–64.