



Description of Neutrophil Cells of Giving Sugar and Honey in Incision Wound of Domestic Cat (*Felis domestica*)

Muhammad Fadhil Shalih¹, Waode Santa Monica², Dwi Kesuma Sari³, and Abdul Wahid Jamaluddin⁴

¹Veterinary Medicine Study Program, Universitas Hasanuddin, Makassar, South Sulawesi, Indonesia

²Division of Veterinary Internal Medicine, Veterinary Medicine Study Program Universitas Hasanuddin, Makassar, South Sulawesi, Indonesia

³Division of Veterinary Pathology, Veterinary Medicine Study Program, Universitas Hasanuddin, Makassar, South Sulawesi, Indonesia

⁴Division of Veterinary pharmacology, Veterinary Medicine Study Program, Universitas Hasanuddin, Makassar, South Sulawesi, Indonesia

*Corresponding authors: waode santa monica (santawaode@med.unhas.ac.id)

Abstract

Neutrophils are one of the most abundant cells of the immune system and are very active during the wound healing process. This study aimed to determine the description and comparison of neutrophil cells after treated sugar and honey in the incision wounds of domestic cats (F. domestica). 15 samples were used with treatment for 14 days and the preparations were given topically. The treatment group consisted of 5 groups, namely Negative control group (NCG) with normal wound healing (without treatment), Positive control group (PCG) given Bioplacenton ointment, treatment group 1 (TG1) used sugar, treatment group 2 (TG2) used honey, Group Treatment 3 (TG3) used combination of sugar and honey. Skin samples were taken on the 4th, 9th, and 14th day of each group to make histopathology preparations and observation under a microscope by assessing the number of neutrophil cells with an indicator score of 0 - 5. Treatment Group 1 (TG1) used sugar shown the best decrease in the number of neutrophil cells with the development of the same healing process like as Treatment Group 3 (TG3) used a combination of sugar and honey, while Treatment Group 2 (TG2) used honey shown also a decrease in the number of neutrophil cells. The three treatment groups showed a better healing process than Negative control group (NCG) without treatment and showed almost equivalent results to the Positive control Group (PCG) used Bioplacenton ointment.

Keywords: *Histopathology, honey, neutrophil, sugar*

Copyright © 2021 JRVI. All rights reserved.

Introduction

Felis domestica is one of the most popular pets in the world and has behavioral characteristics that tend to be active and aggressive. Excessive aggressive behavior in cats can become a serious problem that can result in injury to oneself, other animals or the owner (Tuzio et al., 2004). Wounds are defined as bodily injuries that result in disruption of the structure of the body

(Kirpensteijn and Haar, 2013). The disruption of the skin structure is caused by trauma from sharp and blunt objects, changes in temperature, exposure to chemicals, explosions, electric shocks, or insect bites (Angel *et al.*, 2014). Injuries can also occur as a result of deliberate action, such as wounds in surgical incisions (Tear, 2017).

Wounds that form on the body will trigger the wound healing process. Wound healing refers to a complex and multifactorial process in response to disruption of the normal anatomical structure and function of skin tissue. It is characterized by a series of events, namely, inflammation, cellular phase (granulation), narrowing of the wound area (wound contraction), collagen deposition (collagen formation), epithelial covering (epithelialization), and scar remodeling (keratinization). One of the most active cells during skin wound repair is neutrophils (Ibrahim *et al.*, 2018). Neutrophils play an important role during the inflammatory phase of the wound healing process where the antimicrobial activity of neutrophils is very effective and allows these cells to carry out their main function to prevent the wound from becoming infected (Wilgus *et al.*, 2013).

Healing wounds using alternative materials, it is necessary to know their effectiveness in influencing the number of neutrophils. One of them is using traditional medicine with natural ingredients that can be used to heal wounds, namely sugar and honey. Sugar has the property of reducing the proliferation of bacteria due to its high osmolarity, thereby reducing the moisture content in the wound. Honey has been shown to be effective against bacterial growth, and its use promotes wound healing (Mathews dan Bennington 2002).

The purpose of this study was to describe the effect of giving sugar and honey on the number of neutrophil cells in the incision wounds of domestic cats (*F. domestica*) and provide this new information to educate the public about traditional medicine regarding its use in wound healing in animals.

Materials and Methods

This research was conducted at the Pathology Laboratory of Teaching Animal Clinic of Hasanuddin University. The sample in this study was 15 male domestic cats (*F. domestica*) with normal body weight (2-4 kg) and based on physical examination, they were diagnosed as healthy and active. The sample was divided into 5 groups consisting of negative control group (NCG) normal wound healing (without treatment), positive control group (PCG) given Bioplacenton ointment, treatment group 1 (TG1) given refined sugar, treatment group 2 (TG2) given honey, treatment group 3 (TG3) was given a combination of sugar and honey. All preparations were given topically with a frequency of 2 times a day for 14 days until the wound was completely closed.

The experimental animals were acclimatized for 7 days according to the standard of maintenance management. Furthermore, the process of making the wound with the initial procedure the cat is anesthetized and then incised on the dorsal side. Skin tissue samples were taken on the 4th, 9th and 14th day with an anesthetized cat. The skin samples obtained were then made histopathological preparations with hematoxylin eosin (HE) staining. Microscopic assessment at 400x magnification in one field of view. Observations were made on the rate of neutrophil cell infiltration that was formed in wound healing. Data analysis was descriptive qualitative by comparing the rate of wound healing by looking at the formation of neutrophil cells between treatment groups.

Results and Discussion

The results of histopathological observations of skin tissue in each treatment group showed a difference in the decrease in the number of neutrophil cells. This is shown in the histopathological features of skin tissue on the 4th, 9th and 14th days as follows.

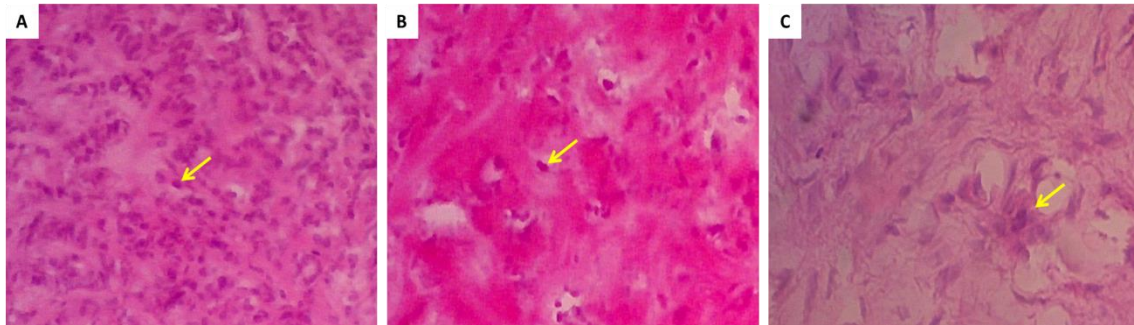


Figure 1. Histopathological Features of the Negative Control Group (without treatment) on (A) 4th day, (B) 9th day and (C) 14th day. Yellow arrows indicate the infiltration of neutrophil cells in the inflammatory process (HE 400x).

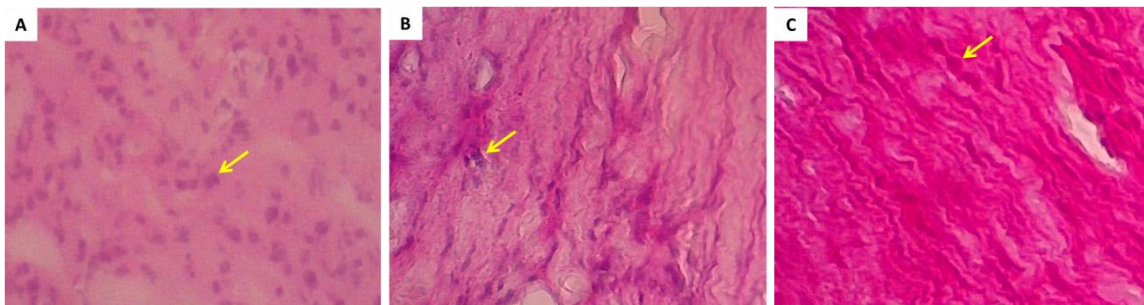


Figure 2. Histopathological Features of the Positive Control Group (Bioplacenton®) topically on (A) 4th day, (B) 9th day and (C) 14th day. Yellow arrows indicate the infiltration of neutrophil cells in the inflammatory process (HE 400x).

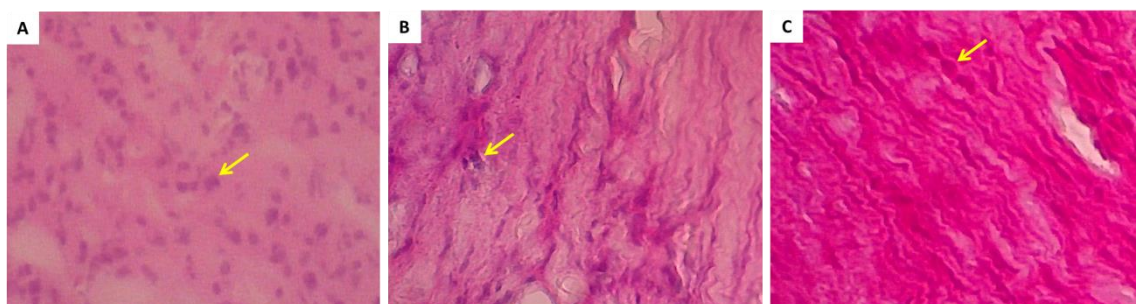


Figure 3. Histopathological Features of Treatment Group 1 (sugar) topically on (A) 4th day, (B) 9th day and (C) 14th day. Yellow arrows indicate the infiltration of neutrophil cells in the inflammatory process (HE 400x).

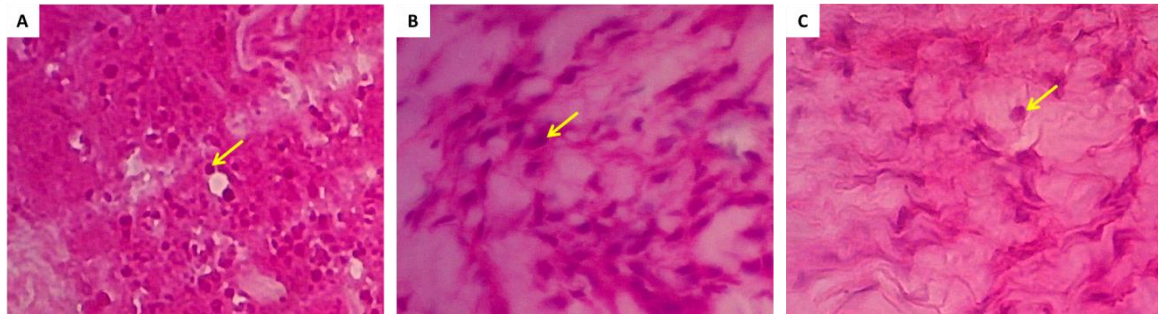


Figure 4. Histopathological Features of Treatment Group 2 (honey) topically on (A) 4th day, (B) 9th day and (C) 14th day. Yellow arrows indicate the infiltration of neutrophil cells in the inflammatory process (HE 400x).

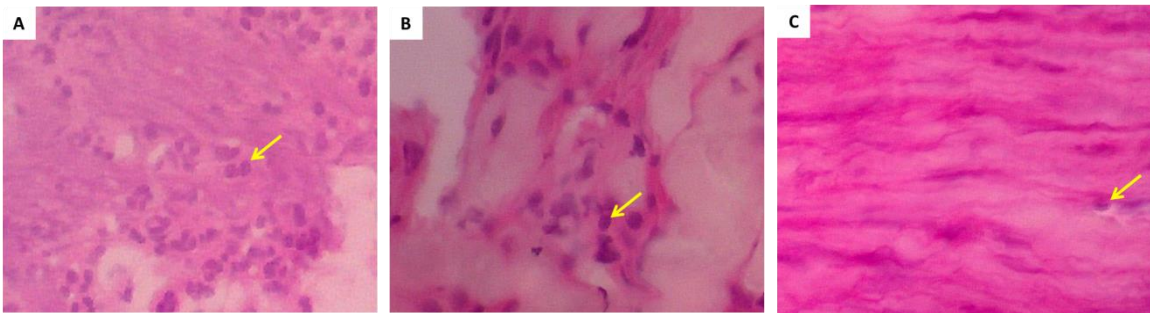


Figure 5. Histopathological Features of Treatment Group 3 (sugar and honey) topically on (A) 4th day, (B) 9th day and (C) 14th day. Yellow arrows indicate the infiltration of neutrophil cells in the inflammatory process (HE 400x).

Table 1. Table of mean score of the number of neutrophil cell infiltrations

Groups	The 4 th day	The 9 th day	The 14 th day
NCG (Without treatment)	5	3	2
PCG (Bioplacenton®)	4	1	0
TG 1 (Sugar)	4	2	1
TG 2 (Honey)	4	3	1
TG 3 (Sugar+ Honey)	4	2	1

Score 0 = There are ≤ 3 neutrophil cell infiltrations per field of view
 Score 1 = There are 4 - 10 neutrophil cell infiltrations per field of view
 Score 2 = There are 11-20 neutrophil cell infiltrations per field of view
 Score 3 = There are 21-30 neutrophil cell infiltrations per field of view
 Score 4 = There are 31 - 40 neutrophil cell infiltrations per field of view
 Score 5 = There are ≥ 41 inflammatory neutrophil cells per field of view

The qualitative data in this study showed that there were differences in neutrophil cell infiltrations on 4th, day 9th and day 14th day between each treatment group (Table 1). On 4th day, the negative control group (NCG) showed a large number of neutrophil cell infiltration spread evenly in the wound area. In this group, there were no visible fibroblast cells and collagen fibers, which indicated that the inflammatory phase was still ongoing in the wound. The number of neutrophil cell infiltration in negative controls was the highest group. This is in accordance with the research of Jannata *et al.* (2014) which states that this is probably due to the absence of active ingredients so that it is possible that there are still microbes that must phagocyte and tissue damage in the wound area is different from the active ingredients in the treatment group. (Agustin *et al.*, 2016). In contrast to the positive control group (PCG),

treatment group 1 (TG1), treatment group 2 (TG2) and treatment group 3 (TG3) where the number of neutrophil cells infiltration in the wound area was less than the negative control group (NCG). This shows that the wound healing process that took place in all treatment groups (TG) was better than the negative control group (NCG). The positive control group (PCG) and all treatment groups (TG) had the same wound healing ability on 4th day, where the histopathological picture showed a decrease in neutrophil cell infiltration and also found fibroblast cells and collagen fibers with a low density at wound tissue.

The fast wound healing process indicates that the application of sugar and honey has properties that can inhibit microbial growth. Honey has hygroscopic properties, which draws water from the surrounding environment, thus creating an environment with a low water concentration with a high osmotic effect so as to attract macrophages. Macrophages will attract fibroblasts to the wound area to initiate collagen synthesis (Zakariya *et al.*, 2009). Apart from the osmotic effect of honey which prevents bacterial growth, honey also contains nutrients and antioxidants, as well as immune stimulation, and other compounds that can help the wound healing process (Puspita *et al.*, 2018). Sugar has hygroscopic properties so it can form hydrogen bonds with water. The presence of hydrogen bonds between water and sugar causes a decrease in the amount of free water and a decrease in the value of water activity (a_w), so that water cannot be used for microbial growth (Biwas *et al.*, 2010).

Observations were made on 9th day, the control group and the treatment group experienced a decrease in the number of neutrophil cell infiltrations, in the negative control group (NCG) fibroblast cells and collagen fibers had begun to appear in low numbers. This is in accordance with the research conducted by Ali *et al.*, (2020) that at this stage the wound healing process has passed the inflammatory phase and entered the proliferation phase resulting in an increase in the number of fibroblast cells and collagen fibers in the wound area.. The number of neutrophil cell infiltration in the positive control group (PCG) given Bioplacenton® experienced the most significant decrease in the range of 4 - 10 neutrophil cell infiltrations per field of view. Meanwhile, treatment group 1 (TG1) given sugar and treatment group 3 (TG3) given a combination of sugar and honey decreased by the same amount in the range of 11-20 neutrophil cell infiltrations per field of view. Then the last treatment group 2 (TG2) was given honey and the negative control group (NCG) experienced a decrease in the number of neutrophil cell infiltration ranges in the range of 21-30 cells.

The positive control group (PCG) giving Bioplacenton® showed the fastest wound healing process on the 9th day then followed by treatment group 1 (TG1) and treatment group 3 (TG3). This shows that the active ingredients in treatment group 1 (TG1) and treatment group 3 (TG3) have a fairly good wound healing ability. Sugar contains TGF- α . TGF- α can activate the integrin α and β receptors which function in fibroblast proliferation and collagen synthesis. Meanwhile, honey has the ability to induce TGF- β which is involved in extracellular matrix reorganization (ECM) and collagen deposition (Ivanalee *et al.*, 2018). Additionally, granulated sugar has an anti-inflammatory effect and promotes granulation by keeping the wound moist. it also stimulates angiogenesis, in which new capillaries are rapidly formed that can transport oxygen and nutrients needed for healing to the wound area (Böhmer, 2015).

The positive control group (PCG) on 14th day had shown that the neutrophil cell infiltration had almost completely disappeared in the wound area. The decrease in the number of neutrophil cells is replaced by collagen fibers to strengthen the newly formed tissue (Ummah *et al.*, 2020). A decrease in the number of low neutrophil cell infiltrations was also seen in all treatment groups (TG) with a decrease in the number of cell infiltrations ranging from 4 to 10 neutrophil cell infiltrations. Then the last was the negative control group (NCG) with a decrease in the number of the range of 11-20 neutrophil cell infiltrations per field of view. The wound healing

process on day 14th in the positive control group (PCG) and all treatment groups (TG) showed an effect on neutrophil cell infiltration. The active ingredient content in each treatment group (TG) showed a good wound healing activity approaching the positive control group (PCG) by administering Bioplacenton®. The same results were shown in a study conducted by Ivanalee *et al.* (2018) who show that applying sugar and honey to the wound area can accelerate the healing process, especially in this phase, sugar and honey play a major role in the process of forming new extracellular matrix (ECM), reepitalization and formation of the collagen matrix.

Conclusion

The application of sugar and honey to the incision wound of a domestic cat affects the number of neutrophil cells in the wound healing process. The sugar treatment group and the combination of sugar and honey treatment group gave a good effect by showing a decrease in the number of neutrophil cells on the 4th, 9th and 14th days which showed almost the same score as the positive control group with Bioplacenton®.

Acknowledgement

The authors would like to thank the assistants and staffs at Laboratory of Pathology, Veterinary Medicine Study Program of Universitas Hasanuddin for their support during this research.

References

- Ali F., Monica WS., Adikurniawan YM., Sari DK., Amir MN. 2020. Fibroblast cell description of provision of sugar and honey in incision wound of domestic cat (*Felis domestica*). Conf. Series: Earth and Environmental Science. 575:1-4.
- Agustin R., Nur D., Suka DR. 2016. Efektivitas Ekstrak Ikan Haruan (*Channa striata*) Dan Ibuprofen Terhadap Jumlah Sel Neutrophil Pada Proses Penyembuhan Luka Studi in Vivo pada Mukosa Bukal Tikus (*Rattus norvegicus*) Wistar. Dentino Jurnal Kedokteran Gigi. 1:68–74.
- Angel PG., Kalangi S., Wangko S. 2014. Gambaran Proses Radang Luka Postmortem pada Hewan Coba [Skrripsi].Manado: Universitas Sam Ratulangi.
- Biwas A, Manish B, Craig H, Rainer G, David A, Horacio. 2010. Use of Sugar on the Healing of Diabetic Ulcers: A Review. Symposium. Journal of Diabetes Science and Technology. 4:1139–1145.
- Böhmer E. 2015. Dentistry in Rabbits and Rodents. UK: Wiley Blackwell.
- Ibrahim N.I, Sok KW., Isa NM., Norazlina M., Kok-Yong C., Soelaiman IN., Ahmad NS. 2018. Wound Healing Properties of Selected Natural Products. Int J Environ Res Public Health 15:2360.
- Ivanalee AS., Ira SY., Maya NY., Nusdianto T., Iwan SH., Amung LS. 2018. Efektivitas Sugar Dressing (100% Gula) Dalam Meningkatkan Kepadatan Kolagen Pada Proses Penyembuhan Luka Bakar Buatan Pada Kulit Tikus Putih (*Rattus Norvegicus*) Jantan. Jurnal Medik Veteriner 1:134–141.
- Jannata RH., Gunadi A., Ernawati E. 2014. Daya antibakteri ekstrak kulit apel manalagi (*Malus sylvestris mill.*) terhadap pertumbuhan *Streptococcus mutans*. E-Jurnal Pustaka Kesehatan. 2: 26–27.
- Kirpensteijn J. dan Haar GT. 2013. Reconstructive Surgery And Wound Management Of The Dog And Cat. UK: Manson Publishing.
- Mathews KA. dan Binnington AG. 2002. Wound Management Using Honey. Compend Contin Edu Pract Vet. 24: 53–59.

- Pavletic MM. 2018. Atlas Of Small Animal Wound Management And Reconstructive Surgery 4th Edition. Iowa: W.B Saunders Comapany.
- Puspita R., Fadil O. dan Desmiwati. 2018. Pengaruh Pemberian Madu Asli Hutan Sijunjung Terhadap Tnf A dan Penyembuhan Luka Pada Tikus Galur Wistar Jantan. Jurnal Kesehatan Andalas 7: 30–32.
- Tear M. 2017. Small Animal Surgical Nursing Third Edition. Canada: Elsevier.
- Tuzio H., Thomas E., James R., Lorraine J. dan Sandra K. 2004. Feline Behavior Guidelines. USA: The American Association Of Feline Practitioners.
- Ummah R, Monica W S, Adikurniawan Y M, Sari D K, Amir M N. 2020. Effects of sugar and honey on the formation of collagen fibers in incision wound of domestic cat (*Felis domestica*). 575:1-4.
- Wilgus TA., Sashwati R., Jodi CM. 2013. Neutrophils and Wound Repair: Positive Actions and Negative Reactions. *Adv Wound Care (New Rochelle)*. 2: 379–388.
- Zakariya, M., Sudiyana IK., dan Erna DW. 2009. Efektifitas Perawatan Luka Insisi Dengan Madu dan Povidon Iodin 10%. *Jurnal Ners*. 4: 1–8.